



## UNDERSTANDING AND INTERPRETING SPECTRAL WAVEFORMS IN THE UPPER AND LOWER EXTREMITIES, PART 2

A 46 year old female presents to her primary care physician for right arm swelling. Her past medical history is significant for prior central venous catheter placement 8 weeks prior for intravenous antibiotics. Her physical examination is significant for significant right arm swelling. The remainder of the physical exam is unremarkable.

The patient was asked to undergo a right upper extremity ultrasound.

Images of her right upper extremity ultrasound are as follows:

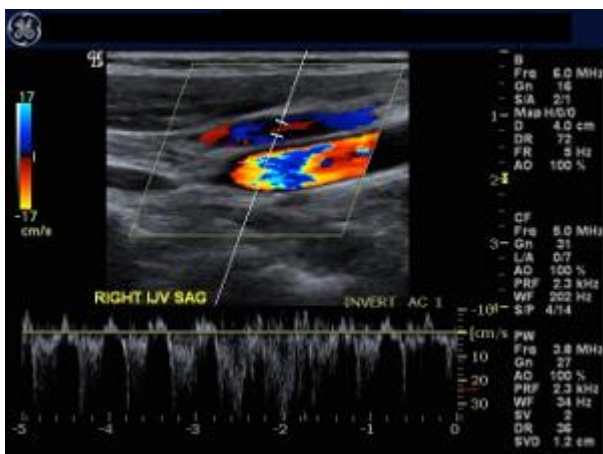


FIGURE 1: Color and Spectral Doppler image of Right Internal Jugular Vein

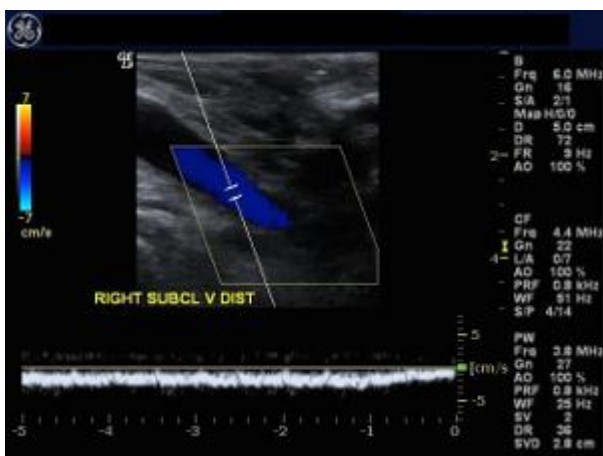


FIGURE 2: Color and Spectral Doppler image of Distal Right Subclavian Vein

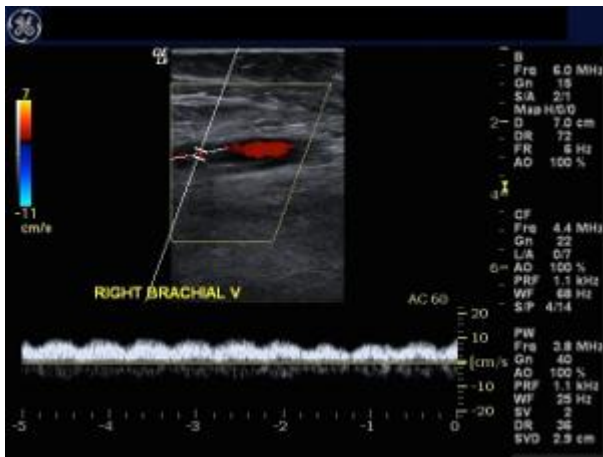


FIGURE 3: Color and Spectral Doppler image of Right Brachial Vein

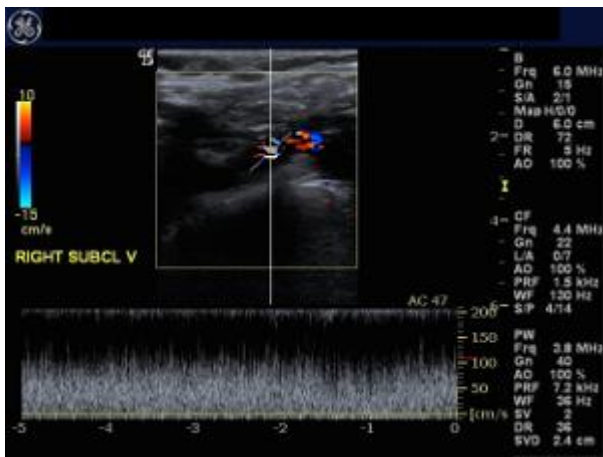


FIGURE 4: Color and Spectral Doppler image of Proximal Right Subclavian Vein

Click below to take the self evaluation quiz for this case. After successfully passing the quiz you can view explanatory notes about the choices as well as references for further reading before proceeding to the next case.

72 year old male presents to his primary care physician for foot numbness and pain. His past medical history is significant for diabetes, tobacco use and prior right sided popliteal artery bypass graft. His physical examination is significant for decreased right lower extremity pulses.

The patient was asked to undergo a right lower extremity ultrasound to assess for patency of his bypass grafts.

Images of his lower extremity ultrasound are as follows:

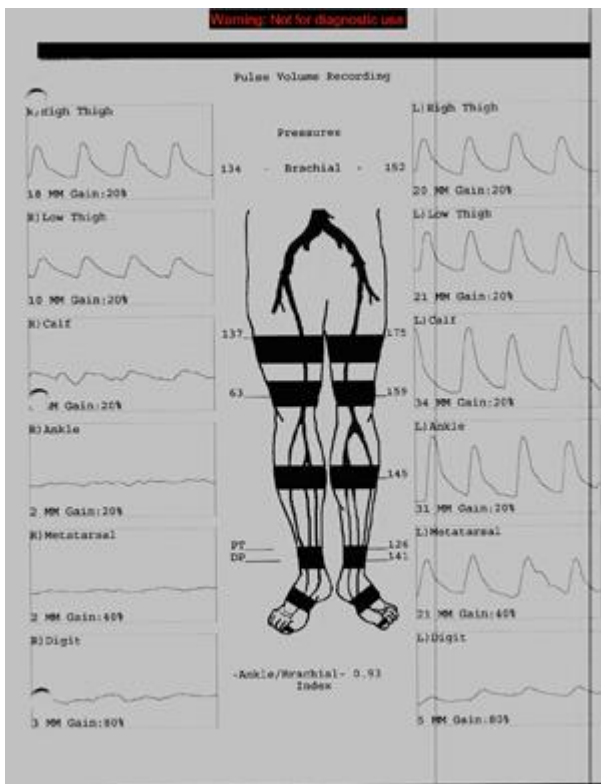


FIGURE 1: Extremity Physiologic Study

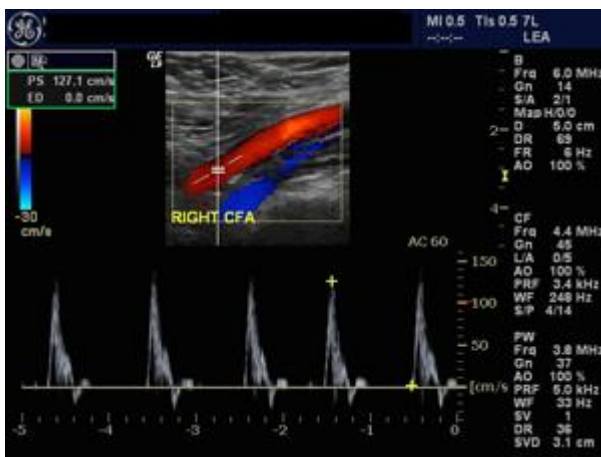


FIGURE 2: Color and Spectral Doppler image of Right Common Femoral Artery

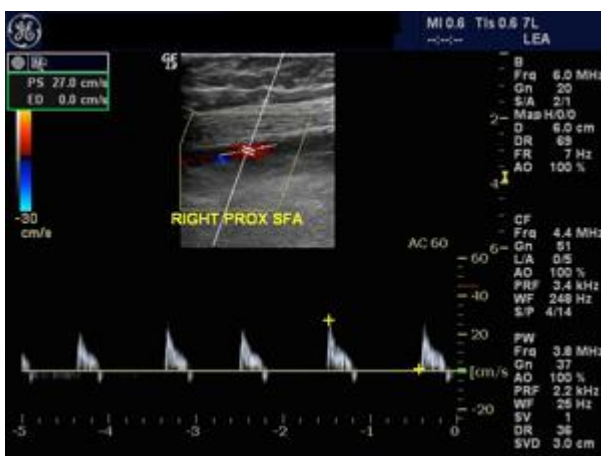

FIGURE 3: Color and Spectral Doppler image of Right Proximal Superficial Femoral Artery

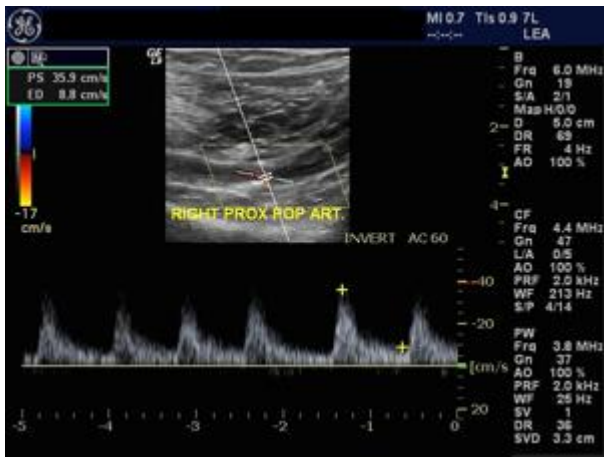


FIGURE 4: Color and Spectral Doppler image of Right Proximal Popliteal Artery.

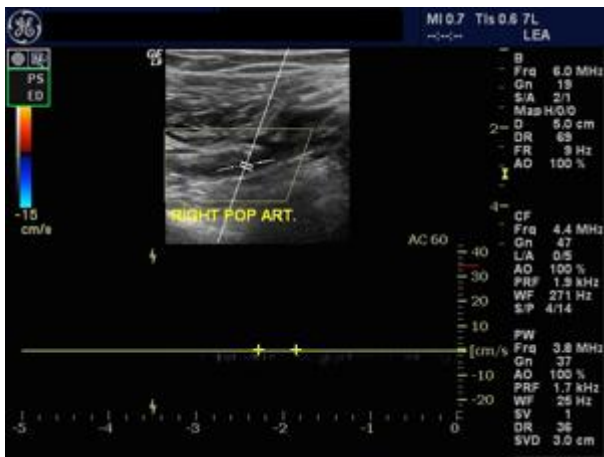


FIGURE 5: Color and Spectral Doppler image of Right Popliteal Artery.

Click below to take the self evaluation quiz for this case. After successfully passing the quiz you can view explanatory notes about the choices as well as references for further reading before proceeding to the next case.

A 28 year old female presents to her primary care physician for right leg swelling. Her past medical history is significant for Protein C Deficiency and oral contraceptive use. Her physical examination is significant for edema and pain involving the right calf.

The patient was asked to undergo a right lower extremity ultrasound. Images of her right lower extremity ultrasound are as follows:

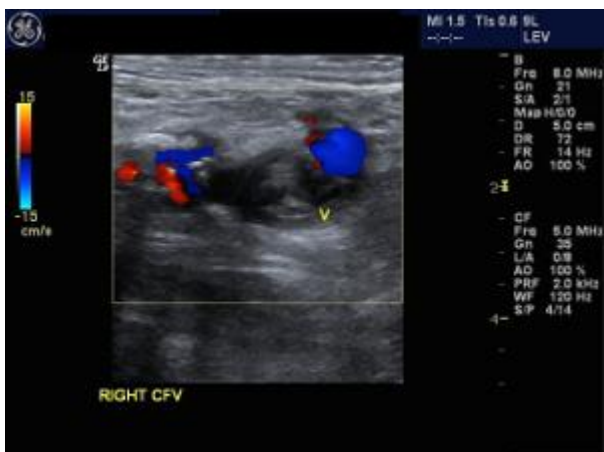

FIGURE 1: Color Doppler image of the right common femoral vein

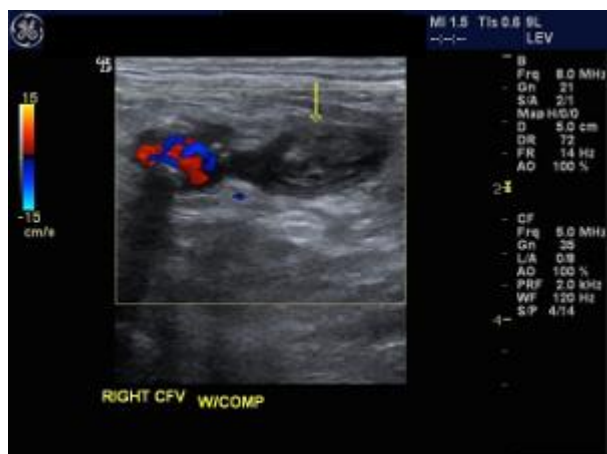

FIGURE 2: Color Doppler image of the right common femoral vein with compression.

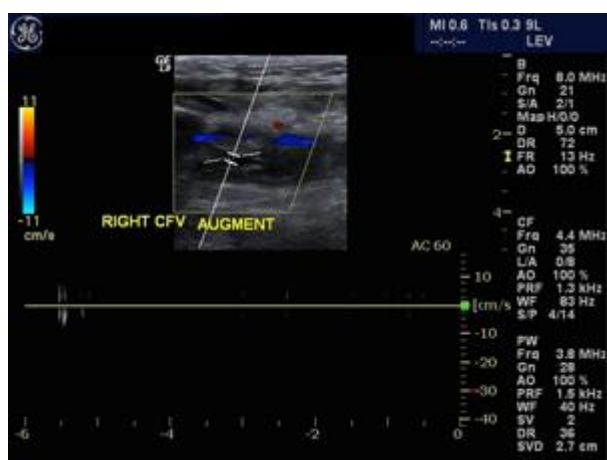

FIGURE 3: Color and Spectral Doppler image of the right common femoral vein.

Click below to take the self evaluation quiz for this case. After successfully passing the quiz you can view explanatory notes about the choices as well as references for further reading before proceeding to the next case.

A 68 year old male presents to his primary care physician for right leg claudication and swelling. His past medical history is significant for hypercholesterolemia, tobacco use and diabetes. His physical examination is significant for decreased pulses in the right lower extremity.

The patient was asked to undergo a right lower extremity ultrasound.

Images of his right lower extremity ultrasound are as follows:



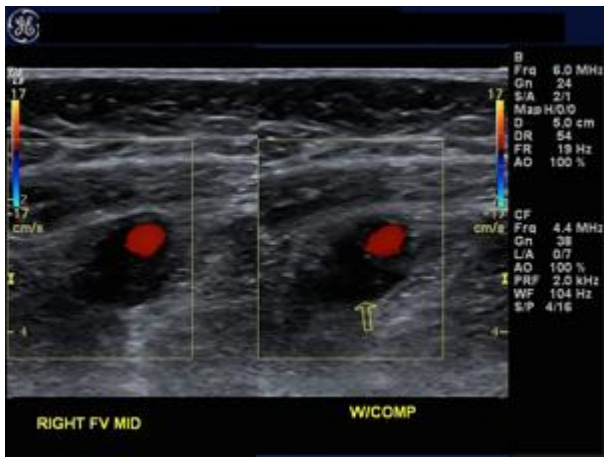


FIGURE 1: Color Doppler image of the mid right superficial femoral artery and vein

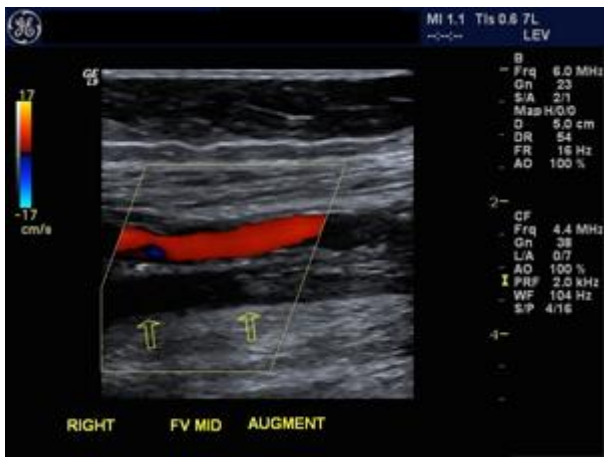


FIGURE 2: Color Doppler image of the mid right superficial femoral artery and vein

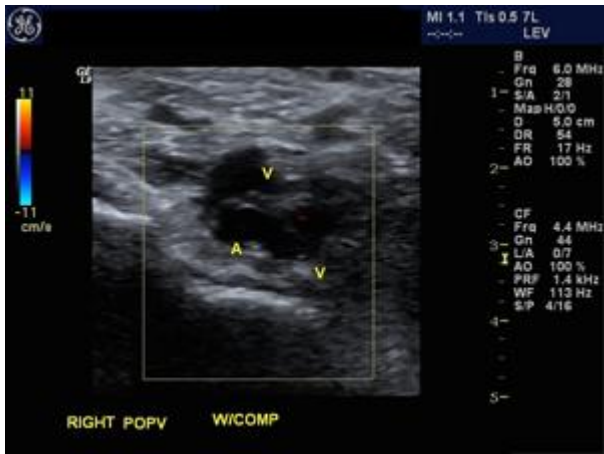

FIGURE 3: Image of the mid right popliteal artery and vein

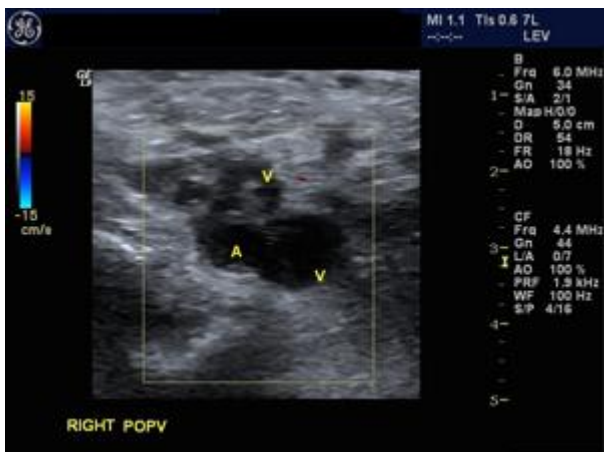

FIGURE 4: Image of the right popliteal artery and vein

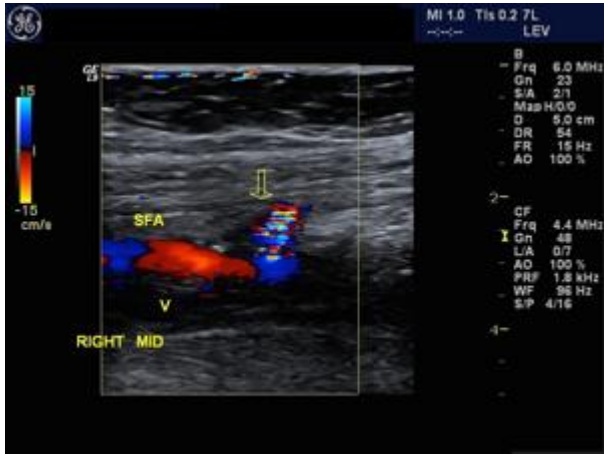

FIGURE 5: Color Doppler image of the mid right superficial femoral artery

Click below to take the self evaluation quiz for this case. After successfully passing the quiz you can view explanatory notes about the choices as well as references for further reading before receiving your CME certificate.